

Osteoid osteoma of the proximal femur: A case report

Ameena Khalid Bughamar (1)

Noora Hamad Alaazmi (2)

Fahad Alkhalifa (3)

(1) Obstetrics and gynecology department, BDF hospital, Kingdom of Bahrain

(2) Internal medicine department, BDF hospital, Kingdom of Bahrain

(3) Orthopedics department, BDF hospital, Kingdom of Bahrain

Corresponding author:

Dr. Ameena Khalid Bughamar

Obstetrics and gynecology department, BDF hospital,
Kingdom of Bahrain

Email: ameenakhalid._@hotmail.com

Received: July 2022 Accepted: August 2022; Published: September 1, 2022.

Citation: Ameena Khalid Bughamar, Noora Hamad Alaazmi, Fahad Alkhalifa. Osteoid osteoma of the proximal femur: A case report. World Family Medicine. 2022; 20(9): 155-160 DOI: 10.5742/MEWFM.2022.9525152

Abstract

Background : Osteoid osteoma “OO” is a benign bone tumor that has a potential to become malignant. It can affect people of all ages, but is most commonly seen in children and young adults. It commonly involves long bones such as femur and tibia. Patients often present with pain that is worse at night and relieved by non-steroidal anti-inflammatory drugs (NSAIDs). Osteoid osteoma can be diagnosed by imaging studies such as X-rays, a Computed tomography (CT) scan and MRI as it classically consists of a central vascularized nidus that represents the neoplastic tissue which can be identified on a CT scan. Many different options are being used in the management of osteoid osteoma ranging from analgesics and physiotherapy to surgical intervention if the conservative management failed to relieve the pain.

Case report: We are presenting a case of a 12 year old male with Proximal femoral OO who was managed conservatively in the beginning and then treated using X-Ray Guided percutaneous Drilling of the lesion with good postoperative clinical outcome. In this Report we are discussing the surgical steps as well as the prognosis compared to other treatment options.

Conclusion: A delay of the diagnosis can occur due to the majority of differential diagnoses and the difficult interpretation of the diagnostic imaging, so a high clinical suspicion and early interventions using more advanced imaging modalities allows earlier diagnosis of “OO” and therefore quicker treatment and relief of patient symptoms.

Keywords:

“OO” osteoid osteoma .

“NSAIDS” by non-steroidal anti-inflammatory drugs.

“CT” Computed tomography .

“MRI” Magnetic resonance imaging.

Introduction

Osteoid osteoma [OO] is a benign osteoblastic tumor, that usually measures less than 2 cm in size and consists of a central vascularized nidus that represents the neoplastic tissue which can be identified on a CT scan [1,2,3]. OO accounts for around 5% of all bone tumors and 11% of benign bone tumors affecting males [1]. It commonly involves long bones such as the femur and tibia [1]. OO classically causes nocturnal pain that is alleviated by NSAIDs [1, 2]. This is a case report of a patient who presented to the Bahrain Defense Force hospital - Royal Medical Services [BDF –RMS] with a diagnosis of an “OO” of the upper femur treated using percutaneous drilling technique.

Case Presentation

A 12 year old male, not known to have any medical problems, presented to the BDF hospital with a history of a progressive left lower limb pain of 6 months duration. The patient described the pain to be dull in nature, scaling 7 out of 10 in pain severity, worsening at night and alleviated by analgesics. He also gave a history of limping over the right side while walking due to the pain. Patient denies any history of trauma or limp injury.

Examination revealed a conscious, alert, vitally stable patient with mild localized tenderness affecting left anterior proximal femur, mainly over the groin region. Overlying skin was normal with no erythema nor ecchymosis and no warmth over the affected area. Patient was having normal motor power and muscle tone with good painless full range of motion of both the hip and knee. Distal neurovascular function was intact as well.

As part of investigations: X-Ray was requested which showed a small radiolucent area affecting proximal femur and part of the neck. CT scan of upper femur was then requested and was followed by MRI which confirmed the diagnosis.

After the radiological diagnosis of “OO”, the patient and his family were advised for surgical excision of the lesion which they agreed to and patient underwent Surgical C-Arm Guided percutaneous Drilling Excision of the OO lesion as planned.

Intraoperative, localization of the tumor was done using C arm guidance. A guide wire was inserted under guidance and was drilled through the target lesion [Figure 3 arrow] aided by Multiplane X-rays. A size 4.5 Cannulated Drill, was then used over the guide wire for drilling of the target lesion which was then followed by a size 6.5 cannulated drill to ensure complete excision (Figures 4, 5). Bone tissue samples were obtained from the Drill bit and were sent for histopathological examination [Figure 6]. Final confirmation of complete excision was done using C arm. Post operatively, the patient was mobilized with full weight bearing over left LL. With aid of Physiotherapy the patient was then discharged in a stable condition and followed up in Outpatient clinic. At two weeks follow-up at the clinic, patient reported complete resolution of the symptoms including night pain and antalgic Gait. Patient continued to follow up with physiotherapy for muscular rehabilitation. He was followed up in the clinic over a period of 6 months where he showed complete recovery with no recurring symptoms or complaints.

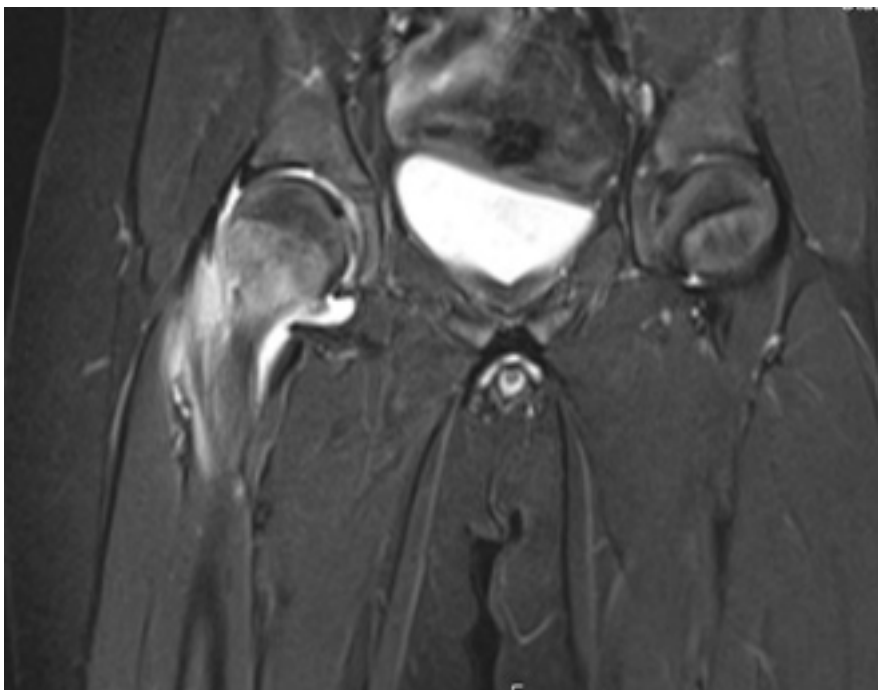


Figure 1: Contrast coronal CT of the upper femur

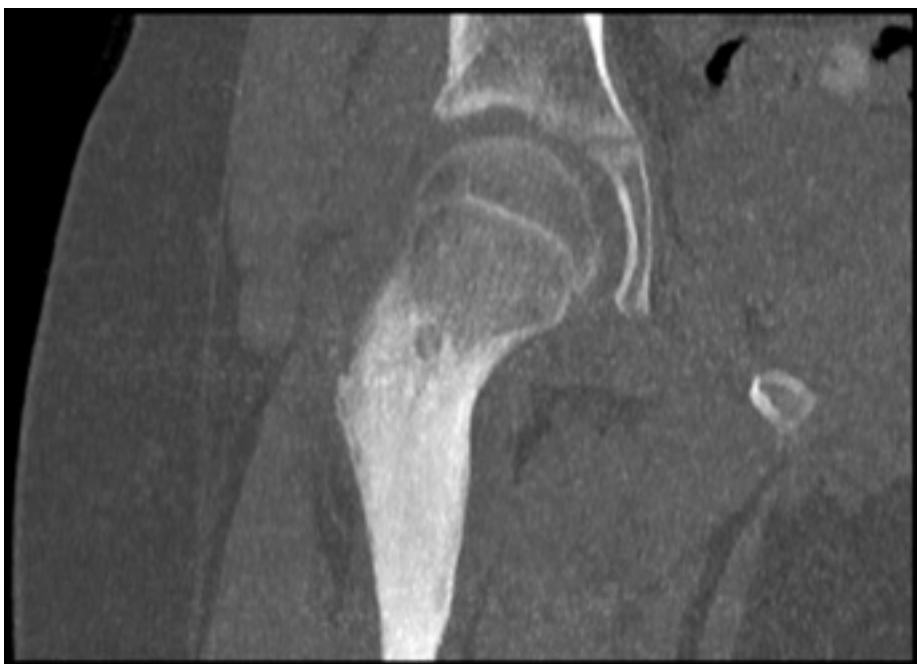

Figure 2: Coronal MRI of the upper femur

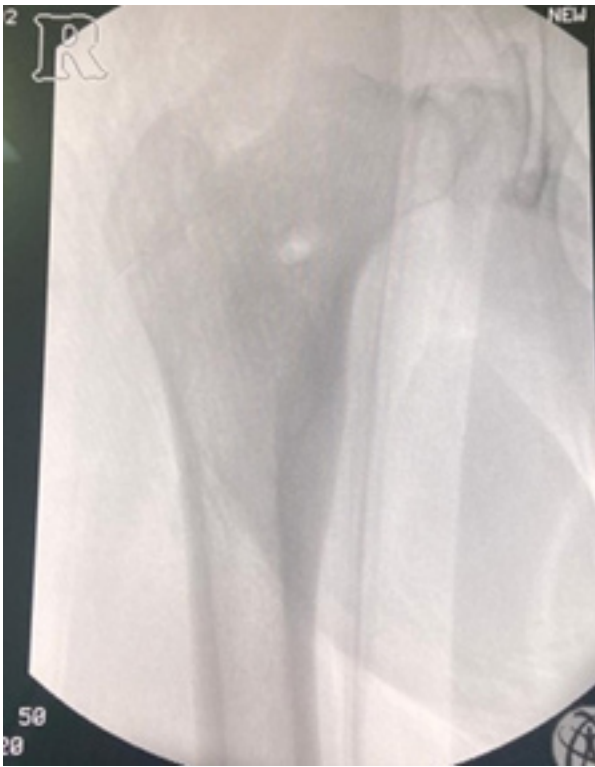

Figure 3: A Guide wire was inserted under guidance and was drilled through target lesion.

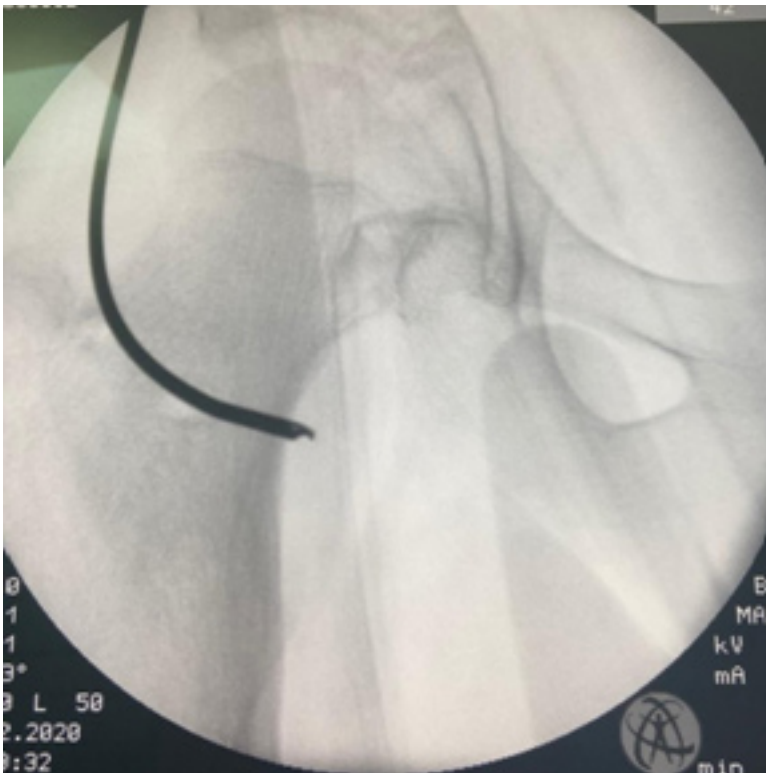


Figure 4: Size 6.5 cumulated drill to ensure complete excision.

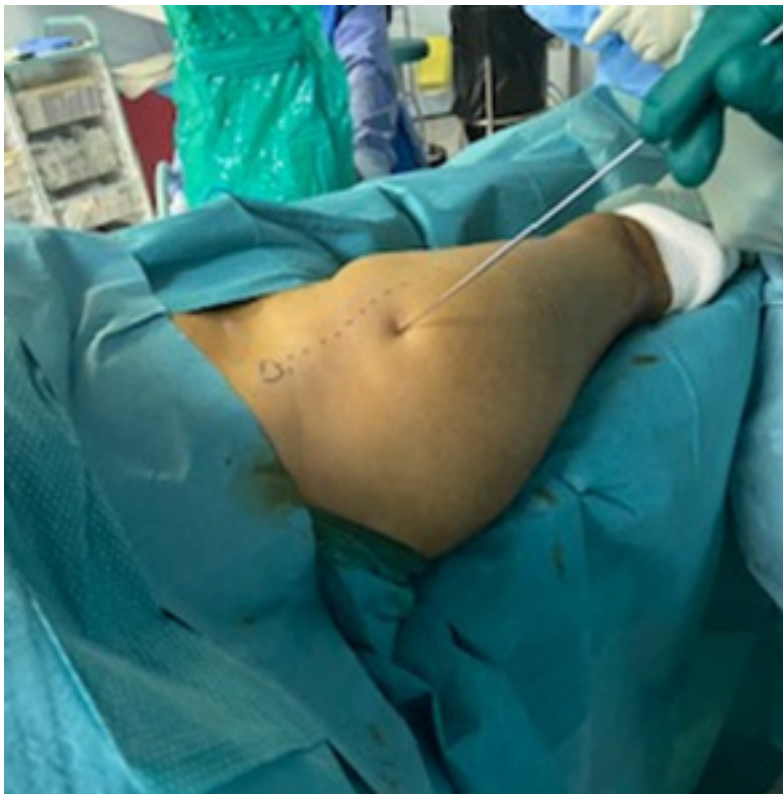

Figure 5 : Bone tissue samples were obtained from the Drill bit and were sent for histopathological examination.

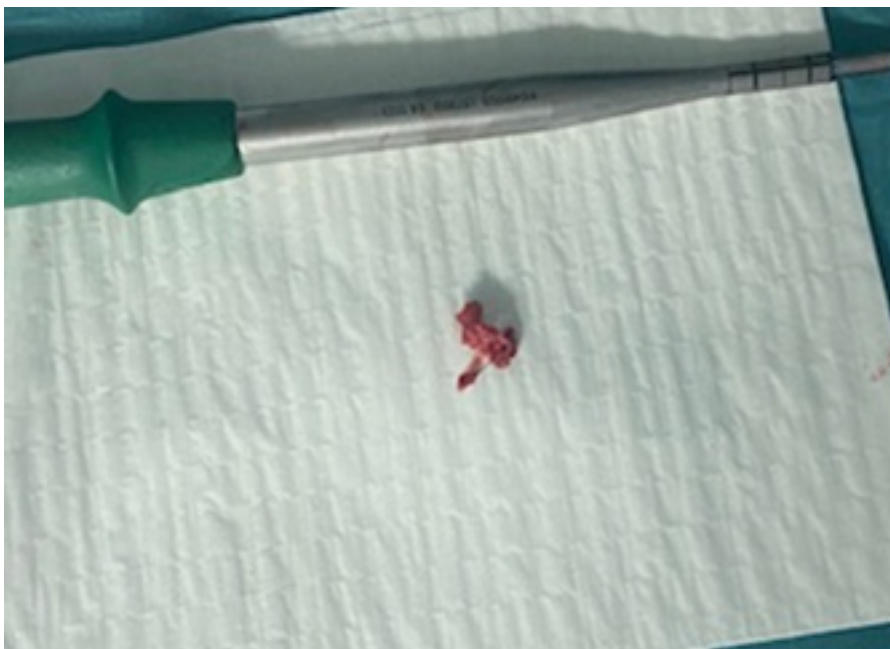


Figure 6 : Final confirmation of complete excision was done using c arm.

Case Discussion

Osteoid osteoma is a benign bone tumor with "OO" making up to 10% as per the literature [2].

People with ages between 5 and 25 are considered the age group in which "OO" is usually found, with a male gender predominance as they are 3 times more affected than female gender [1,3].

"OO" is subdivided into 3 variants as per the literature; cortical, cancellous, or subperiosteal, out of which cortical lesions were considered the most common variant.

Patients with "OO" are usually presenting with nocturnal pain that is progressive and dull in character and which is relieved by NSAIDs.

Our patient was complaining as well from the night pain which was relieved by the analgesics given to him and this presentation supports that osteoid osteoma is one of the top differential diagnoses.

Plain radiography is the initial investigation of choice in any other bone tumors [1].

The appearance of an osteoid osteoma on a plain radiograph is a classically small, round, radiolucent nidus with surrounding sclerosis and this was the finding in our patient's X-Ray as it was the first modality of investigation that was done for him as discussed above.

The nidus itself may contain an area of calcification.

The double density sign is a characteristic of OO that is seen in three phase bone scintigraphy in which there is intense focal uptake centrally and an area of less uptake in the peripheral area or in other words the area surrounding the dense central uptake.

A CT scan is considered the radiological imaging of choice in "OO" as it can clearly identify the characteristic central target shaped nidus [1,2,3,4].

Our patient was ordered to do a CT scan and MRI to confirm the diagnosis and it reported the presence of a well-defined cortical thickening in the anterior side of the proximal femoral metadiaphysis extending to the lower side of the neck of the femur [figures 1, 2], as well as a small area of radiolucency in the anterior side of the lower neck of the femur with a small central nidus that goes with the diagnosis of OO.

However, bone marrow edema shown on MRI can mask the typical features of the tumor, so MRI is less useful than CT for the evaluation and the diagnosing of "OO". It is however more accurate than CT in diagnosing cancellous lesions [1,2,3,4].

Treatment options for "OO" can be divided into two types; the first one is operative and the second is non-operative management [1].

Non-operative treatments include medication such as administration of aspirin or other NSAIDs to relieve

the pain [2]. However, operative treatments are also considered as an option especially in patients with failure of medical treatments or those with high risk of renal and gastrointestinal complications due to the chronic use of NSAIDs [1].

However, there are many surgical options such as: en bloc resection, CT-assisted percutaneous radiofrequency, CT-assisted percutaneous en-bloc excision, CT-assisted percutaneous thermocoagulation, open intra-lesional curettage, CT-assisted percutaneous radiofrequency ablation, CT-assisted percutaneous en bloc excision and CT-assisted percutaneous laser photocoagulation [3,4].

The Radio frequency ablation is used whereby the nidus is located by the guidance of CT scan and burned by radio frequency waves through a needle placed inside the nidus [1,2]. However, there are other approaches including the en bloc resection in which the entire nidus is removed surgically [1,3].

Our patient was given a trial of analgesics and physiotherapy for 6 months. However, this line of management failed and surgery was warranted, so our patient underwent Surgical C-Arm Guided percutaneous Drilling Excision of the OO lesion as discussed above.

Conclusion

Our patient had a satisfactory outcome from the surgery and was able to mobilize immediately after the surgery with complete resolution of symptoms and that is all in favour of the early interventions using more advanced imaging modalities such as CT scan and MRI which allows earlier diagnosis of "OO" and therefore quicker treatment and relief of patient symptoms.

Sources of funding:

Nothing to declare.

Ethical approval: Approved from the Bahrain Defence Force Royal Medical services research and research ethics committee has been attained.

Consent:

Written and signed Consent from the patient has been obtained.

References

- Noordin, Shahryar, et al. "Osteoid osteoma: contemporary management." *Orthopedic reviews* 10.3 (2018).
- Hashemi, Jahanbakhsh, et al. "Radiological features of osteoid osteoma: pictorial review." *Iranian Journal of Radiology* 8.3 (2011): 182.
- Canella, Clarissa. "Osteoid osteoma: diagnosis and treatment Osteomaosteoid: diagnóstico e tratamento."
- Jordan, Robert W., et al. "Osteoid osteoma of the foot and ankle—a systematic review." *Foot and Ankle Surgery* 21.4 (2015): 228-234.