

Elastography as predictor for thyroid nodule malignancy

Abdulaziz ALjuaid ¹, Nermeen Omar ², Sultanah Alshreef ³, Yazeed Alharthi ¹,
Mohannad Algarni ¹, Omar J. AlThaqafi ³, Reyad ALSuqair ¹

(1) Medical intern, Taif University School of Medicine, Taif, Saudi Arabia.

(2) Department of Radiology, Ain Shams University, Cairo, Egypt.

(3) Department of Radiology and Medical Imaging, Alhada Armed Forces Hospital, Taif, Saudi Arabia.

Corresponding author:

Dr. Omar J. AlThaqafi

Department of Radiology and Medical Imaging,

Alhada armed Forces hospital,

Taif, Saudi Arabia.

Email : Omar.althaqafi@hotmail.com

Received: September 2022 Accepted: October 2022; Published: November 1, 2022.

Citation: Omar J. AlThaqafi et al. Elastography as predictor for thyroid nodule malignancy. World Family Medicine. 2022; 20(11): 69-76. DOI: 10.5742/MEWFM.2022.95251378

Abstract

Background: Ultrasound elastography is a promising noninvasive technique that is still in its infancy. It uses tissue elasticity measurements to distinguish between benign (soft tissues) and malignant (hard tissues) nodules.

Objectives: to see if elastography has diagnostic significance and if it may be used as a predictor of thyroid nodule malignancy

Methods: An analytical cross-sectional study was done and data collected using Philips Epiq 7 linear transducer 8-12MHZ, strain type of elastography. A sample of 27 patients from Al-Hada Armed Forces Hospital, Taif, Saudi Arabia were included. Data about patients' demographics, AP, TR, Echogenicity, Margin, Composition, Echogenic foci, FNA result, Elastography findings and TIRADs classification were collected.

Results: According to FINA findings, the majority of patients (96.3 percent) had a benign tumour, and 81.5 percent had soft elastography. T2 was the most common TIRADs classification (55.6 percent). The percentage of patients with T2 (TIRADs) was significantly greater in patients with a younger mean age, and there was a non-significant association between TIRADs categorization and FINA findings. Females had a much higher percentage of benign diagnoses based on FINA results, with no significant link detected between FINA results and the demographic or clinical characteristics of the patients. Both TIRADs categorization and FINA results were shown to have no significant link with the elastography data.

Conclusion: The elastography findings were found to have a non-significant link with both TIRADs categorization and FINA results. Future studies with larger samples should be conducted to clarify the study outcomes.

Keywords: Elastography, predictor, thyroid, nodule, malignancy

Introduction

Thyroid nodules are a common discovery, and the use of ultrasound (US) has helped to raise awareness of them (1). While the majority of thyroid nodules are asymptomatic and benign, ruling out cancer, which occurs in around 5-10% of all nodules, is a major challenge in their treatment (2).

The gold standard for distinguishing benign from malignant thyroid nodules is fine-needle aspiration biopsy (FNAB), although in 0.7-15 percent of cases, thyroid lobectomy is required to make a definite diagnosis. It's also a more invasive operation with a larger price tag (3,4).

Thyroid Imaging Reporting and Data System is one of the techniques suggested for standardized reporting and assessment (TIRADS). TIRADS have the advantage of improving patient care and cost-effectiveness by avoiding unnecessary fine needle aspiration biopsy (FNAB) in thyroid nodule patients (6). According to the American College of Radiology (ACR), it is divided into five categories: i) Not Suspicious; ii) Benign; iii) Mildly Suspicious; iv) Moderately Suspicious; v) Highly Suspicious (7).

Ultrasound elastography is a valuable noninvasive tool that is still relatively young. It's based on measuring tissue elasticity and can tell the difference between benign (soft tissues) and malignant (hard tissues) nodules (8,9). Shear wave elastography (SWE) and strain real-time elastography (RTE) were both found to be efficient in identifying increased stiffness as a marker for suspected neoplasm, with RTE exhibiting superior findings (8,9).

The use of a high-resolution ultrasound and elastography together allows for the identification of circumstances when a FNA is not necessary (10). The mean sensitivity and specificity for the diagnosis of malignant thyroid nodules were 92 percent and 90 percent, respectively, according to a meta-analysis of real-time ultrasound (11). According to a study published in 2021, adding SRE to TIRADS improves its sensitivity and negative predictive value (12).

Several studies have found that ultrasonic elastography (USE) has lower sensitivity and specificity than standard US (13,14). However, no clear recommendations have been made about its use alone, with TIRADS classification in conjunction with fine needle aspiration (FNA) for thyroid nodule evaluation, and Elastography considered a potential new approach.

This study aimed to evaluate the diagnostic value of elastography and if it can be used as a predictor for thyroid nodule malignancy.

Subjects and Methods

Data of the present study was collected using Philips Epiq 7 linear transducer 8-12MHZ, strain type of elastography. A non-probable sampling technique was utilized and sample size of 27 candidates was targeted. The study was an analytical cross-sectional study done between November 2021 and January 2022 at Al-Hada Armed Forces Hospital, Taif, Saudi Arabia.

Sample size: 27 candidates from the Radiology Department at Al-Hada Armed Forces Hospital, Taif, Saudi Arabia were the sample of the study.

Study participants: the inclusion criteria were patients of all ages, genders, size for nodule, solid nodule, nearly solid nodule, adequate sample histopathology report, TIRAD 3,4 AND 5. And the exclusion criteria were patients with any cystic nodule, nearly cystic nodule, non-adequate samples histopathology report, TIRAD 1 AND 2.

Data collection: a pre-designed checklist was prepared to collect data about patients' age, gender, AP, TR, Echogenicity, Margin, Composition, Echogenic foci, FNA result, Elastography findings and TIRADs classification.

Ethical considerations: Ethical approval for the study was obtained from medical services general directorate M.S.D research & ethics committee western region Al-Hada Armed Force hospital- Taif, on 1-Nov-2021, approval number: 2021-599 .

Data analysis: The SPSS program version 26 was used analyze the data. The Chi-squared test (χ^2) was used to assess the association between qualitative data reported as numbers and percentages. Quantitative data was presented as mean and standard deviation (Mean \pm SD). To assess the relationships between quantitative variables, the One-Way ANOVA test, Kruskal Wallis test, the Independent sample t-test and the Mann Whitney test were used according to the data normality. A p-value of less than 0.05 was considered statistically significant.

Results

Table 1 shows that the mean age of studied patients was 48.3 ± 11.77 years. Their mean AP and TR were 16.11 ± 10.87 and 21.56 ± 12.19 respectively. Most of patients were females (85.2%). The echogenicity of most of patients (63%) was Iso; 92.6% had a smooth margin and 44.45 had a solid composition. None of patients had an echogenic focus. Most patients (96.3%) had a benign tumor based on FINA results and 81.5% had a soft elastography. The most common TIRADs classification was the T2 (55.6%).

Table 2 shows that patients with a younger mean age had a significant higher percentage of those who had T2 (TIRADs) classification ($p < 0.05$). On the other hand, a non-significant relationship was found between TIRADs classification and all other patients' demographic or clinical data ($p > 0.05$).

Figure 1 illustrates a non-significant relationship between TIRADs classification and FINA results ($p > 0.05$).

Table 3 shows that females had a significantly higher percentage of having a benign diagnosis based on FINA results compared to male patients ($p < 0.05$). On the other hand, a non-significant relationship was found between FINA results and patients' demographic or clinical data ($p > 0.05$).

Table 4 shows that a non-significant relationship was found between Echogenicity and patients' demographic or clinical data ($p > 0.05$).

Table 1. Distribution of the studied patients according to their demographic and clinical data (No. 27)

Variable	No. (%)
Age	48.3 ± 11.77
AP	16.11 ± 10.87
TR	21.56 ± 12.19
Gender	
Female	23 (85.2)
Male	4 (14.8)
Echogenicity	
Hyper	3 (11.1)
Hypo	7 (25.9)
Iso	17 (63)
Margin	
lobulated	2 (7.4)
Smooth	25 (92.6)
Composition	
Cystic and solid	2 (7.4)
Solid	12 (44.4)
Solid and cystic	3 (11.1)
Spongiform	10 (37)
Echogenic foci	None
FNA result	
Benign	26 (96.3)
Malignant	1 (3.7)
Elastography	
Hard	5 (18.5)
Soft	22 (81.5)
TIRADs	
T1	4 (14.8)
T2	15 (55.6)
T3	1 (3.7)
T4	6 (22.2)
TR5	1 (3.7)

Table 2. Relationship between TIRADs classification and patients' demographic and clinical data (No.:27)

Variable	TIRADs					χ^2	p-value
	T1	T2	T3	T4	T5		
Age	63 ±14.72	43.6 ±10.23	59 ±0.001	47.67 ±5.57	53± 0.001	3.23*	0.031
AP	17 ±14.98	17.2 ±12.61	9 ±0.001	15.17 ±2.99	9 ±0.001	4**	0.851
TR	26.75± 18.55	20.87 ±13.28	16± 0.001	21.67± 6.12	16± 0.001	4**	0.862
Gender							
Female	3 (13)	13 (56.5)	1 (4.3)	6 (26.1)	0 (0.0)	7.32	0.12
Male	1 (25)	2 (50)	0 (0.0)	0 (0.0)	1 (25)		
Echogenicity							
Hyper	0 (0.0)	1 (33.3)	0 (0.0)	2 (66.7)	0 (0.0)	8.33	0.401
Hypo	1 (14.3)	3 (42.9)	0 (0.0)	2 (28.6)	1 (14.3)		
Iso	3 (17.6)	11 (64.7)	1 (5.9)	2 (11.8)	0 (0.0)		
Margin							
Lobulated	0 (0.0)	2 (100)	0 (0.0)	0 (0.0)	0 (0.0)	1.72	0.786
Smooth	4 (16)	13 (52)	1 (4)	6 (24)	1 (4)		
Composition							
Cystic and solid	1 (50)	1 (50)	0 (0.0)	0 (0.0)	0 (0.0)	8.55	0.741
Solid	0 (0.0)	8 (66.7)	1 (8.3)	3 (25)	0 (0.0)		
Solid and cystic	1 (33.3)	1 (33.3)	0 (0.0)	1 (33.3)	0 (0.0)		
Spongiform	2 (20)	5 (50)	0 (0.0)	2 (20)	1 (10)		
FNA result							
Benign	4 (15.4)	14 (53.8)	1 (3.8)	6 (23.1)	1 (3.8)	0.83	0.934
Malignant	0 (0.0)	1 (100)	0 (0.0)	0 (0.0)	0 (0.0)		
Elastography							
Hard	0 (0.0)	2 (40)	0 (0.0)	2 (40)	1 (20)	6.64	0.154
Soft	4 (18.2)	13 (59.1)	1 (4.5)	4 (18.2)	0 (0.0)		

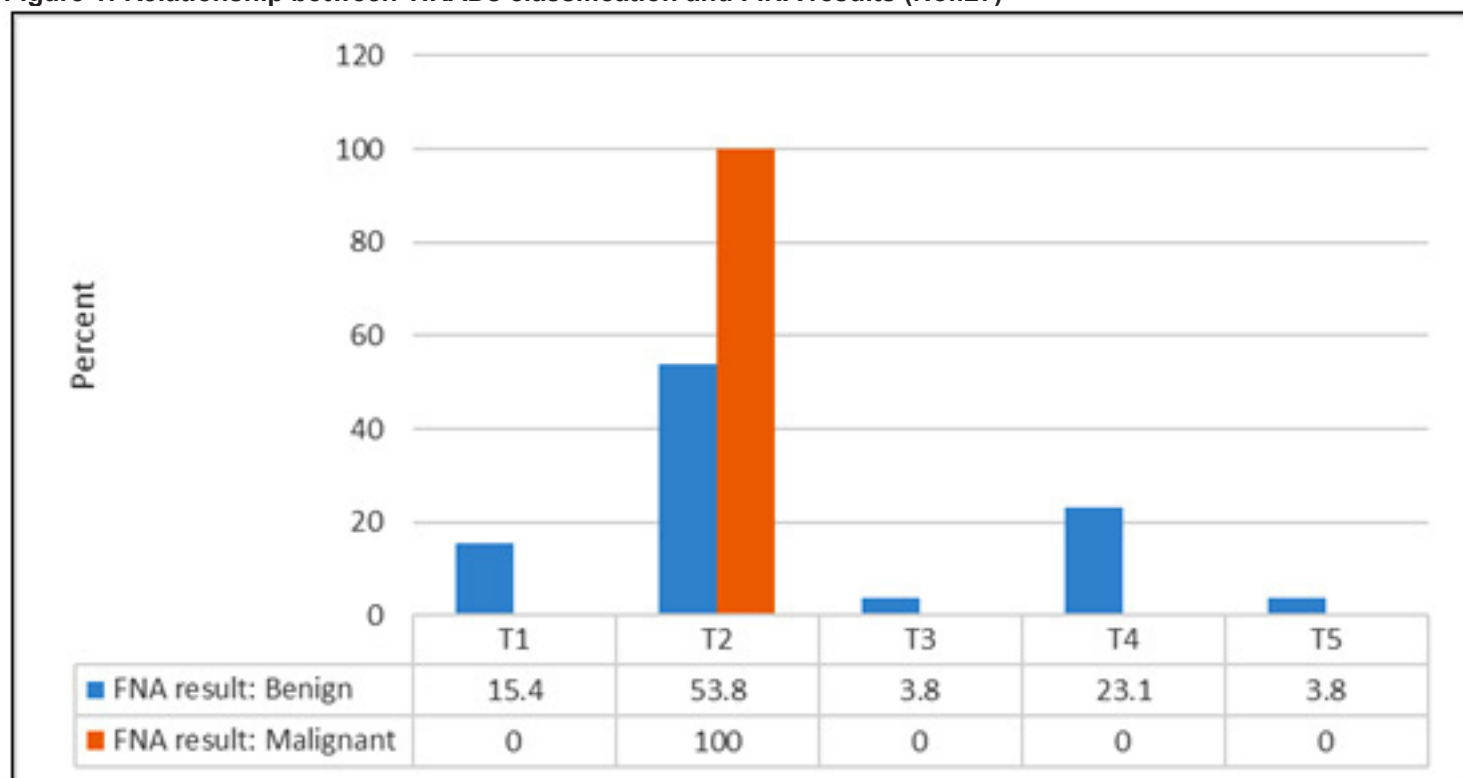
N.B.: * = One -Way ANOVA test ** = Kruskal Wallis test

N.B.: T1=I) Not Suspicious; T2= Benign; T3= Mildly Suspicious; T4= Moderately Suspicious; T5=Highly Suspicious.

TIRADs

	T1	T2	T3	T4	T5
FNA result: Benign	15.4	53.8	3.8	23.1	3.8
FNA result: Malignant	0	100	0	0	0

Figure 1: Relationship between TIRADs classification and FINA results (No.:27)



N.B.: ($\chi^2 = 0.83$, p-value = 0.934)

Table 3: Relationship between FINA results and patients' demographic and clinical data (No.:27)

Variable	FINA result		χ^2	p-value
	Benign No. (%)	Malignant No. (%)		
Age	47.81 ± 11.73	61 ± 0.001	1.1*	0.28
AP	15.42 ± 10.47	34 ± 0.001	0.19**	0.296
TR	21.54 ± 12.43	22 ± 0.001	0.74	0.815
Gender				
Female	23 (100)	0 (0.0)	5.97	0.015
Male	3 (71)	1 (25)		
Echogenicity			2.96	0.227
Hyper	3 (100)	0 (0.0)		
Hypo	6 (85.7)	1 (14.3)		
Iso	17 (100)	0 (0.0)		
Margin			0.08	0.773
Lobulated	2 (100)	0 (0.0)		
Smooth	24 (96)	1 (4)		
Composition			1.29	0.73
Cystic and solid	2 (100)	0 (0.0)		
Solid	11 (91.7)	1 (8.3)		
Solid and cystic	3 (100)	0 (0.0)		
Spongiform	10 (100)	0 (0.0)		
Elastography			0.23	0.627
Hard	5 (100)	0 (0.0)		
Soft	21 (95.5)	1 (4.5)		

N.B.: * = Independent sample t-test ** = Mann Whitney test

Table 4. Relationship between Echogenicity and patients' demographic and clinical data (No.:27)

Variable	Echogenicity			χ^2	p-value
	Hyper No. (%)	Hypo No. (%)	Iso No. (%)		
Age	44.33 ± 6.8	48 ± 8.44	49.12 ± 13.75	2	0.82
AP	24.33 ± 12.7	13.86 ± 9.56	15.59 ± 11.06	0.2	0.216
TR	27.33 ± 10.01	15.86 ± 8.72	22.88 ± 13.35	0.31	0.358
Gender					
Female	2 (8.7)	5 (21.7)	16 (69.6)	2.94	0.23
Male	1 (25)	2 (50)	1 (25)-		
Margin					
Lobulated	0 (0.0)	0 (0.0)	2 (100)	1.27	0.53
Smooth	3 (12)	7 (28)	15 (60)		
Composition					
Cystic and solid	0 (0.0)	0 (0.0)	2 (100)	6.78	0.342
Solid	2 (16.7)	2 (16.7)	8 (66.7)		
Solid and cystic	0 (0.0)	0 (0.0)	3 (100)		
Spongiform	1 (10)	5 (50)	4 (40)		
Elastography					
Hard	1 (20)	1 (20)	3 (60)	0.52	0.768
Soft	2 (9.1)	6 (27.3)	14 (63.6)		

Discussion

The aim of this study was to determine if elastography had diagnostic significance and if it may be utilized as a predictor of thyroid nodule malignancy.

There were 27 patients in the current study. One of the study's findings was that patients with a younger mean age had a larger percentage of those classified as T2 (TIRADs). In addition, female patients had a significantly higher percentage of benign diagnoses based on FINA results than male patients.

Previous studies found that the risk factors for thyroid nodules include female gender, advanced age, iodine deficiency, and previous head and neck radiation (15,16).

Patients with a T2 categorization had a 100% malignancy rate, according to our research. A prior study discovered that TR 3 individuals had a 22.7 percent malignancy risk. We used the most recent ACR TIRADS criteria from 2017. (17). Previous versions of the TIRADS categorization have been utilized in other investigations (ACR TIRADS 2009, K TIRADS 2017 and EU TIRADS 2017). Barbosa et al. (18) reported a percentage of malignancy of 23.3 percent in participants with TR 3 using the most recent ACR TIRADS 2017 criteria. According to the 2017 ACR TIRADS criteria, there are four probable TR3 scenarios: Solid and hyperechoic; solid and isoechoic; mixed solid cystic and hyperechoic with macrocalcification; mixed solid cystic and hypoechoic. Individual traits like macrocalcification or the hyperechoic nature of the nodule was not included as possible features to predict malignancy in prior systems,

which could explain the greater probability of malignancy in TR3. This could be one of ACR TIRADS 2017's disadvantages (17,18).

Thyroid nodules are now divided into five TIRADS categories based on five descriptors (composition, echogenicity, shape, margin, and echogenic foci/calcification). Each description is assigned a point, and the TIRADS score is derived by summing all of the points from all descriptors. Solid nodules, hypoechogenicity, uneven edges, microcalcifications, and a form taller than wide on a transverse view are all sonographic observations that point to malignancy (19).

Fine needle aspiration cytology (FNAC) is a valuable technique for developing a systematic strategy to the clinical care of thyroid nodules and determining the appropriate surgical method when surgery is required. Thyroid FNA is expected to have a high degree of sensitivity and specificity, similar to other clinical tests in medicine. As a result, thyroid FNA reporting should be as near to similar as possible among pathologists to allow for logical management methods and avoid clinician confusion (20,21).

One of these work results was that a non-significant relationship was found between TIRADs classification and FINA results. The sensitivity, specificity, accuracy, positive predictive and negative predictive value of FNAC were 80 percent, 90 percent, 85 percent, 86 percent, and 86.6 percent, respectively, whereas TIRADS were 80 percent, 47.2 percent, 61 percent, 51.3 percent, and 77.3 percent in a prior study (17). TIRADS classification was equally sensitive and specific as FNAC classification.

Microcalcification was the most sensitive (80%) and specific (100%) of the individual USG measurements (86 percent). According to the findings, USG and FNAC are similarly sensitive in detecting malignant thyroid nodules, however FNA is more specific (90 percent). It's a non-invasive technique that may accurately discriminate between malignant and benign tumours (85 percent).

In the present study, a non-significant relationship was found between Elastography and both TIRADs classification or FINA results. Ultrasound was found to help in differentiating benign from malignant thyroid nodules. However, individual US features may be of limited value (22,23).

False negative and false positive outcomes are among FNAC's drawbacks. Bloch (24) conducted a comparison research between FNAC and histology and discovered that FNAC had a 91.6 percent accuracy rate. A comparable study by Mundasad et al. (25) discovered that FNAC had a sensitivity (52.6%), specificity (86.6%), and accuracy (79.1%) for thyroid cancer. In a comparable study, Handa et al. (26) found that FNAC had a sensitivity of 97 percent, a specificity of 100 percent, a positive predictive value of 96 percent, and a negative predictive value of 100 percent.

Elastography is a newly discovered dynamic technology that employs ultrasound to quantify tissue stiffness by detecting the degree of deformation when an external force is applied. Elastography uses tissue deformation, or strain, generated by compression and is measured by precompression and postcompression ultrasonic signals, similar to palpation in the assessment of the thyroid during physical examination (27). Significant differences in stiffness between normal thyroid tissue and pathologic thyroid tissue have been discovered using thyroid elastography. Although US elastography is not yet widely utilised in clinical practice, it has been found to be helpful in distinguishing between benign and malignant breast (28) and prostate lesions (29). When compared to standard US, US elastography is less stressful for patients, is simple to conduct, and takes only a few minutes longer to complete (30).

FNAC is the most accurate and cost-effective approach for evaluating thyroid nodules, according to the Revised American Thyroid Association Management Guidelines for Patients with Thyroid Nodules and Differentiated Thyroid Cancer (9). The fact that 10–15 percent of FNAC cytology specimens are non-diagnostic and 10–20 percent are indeterminate is a serious constraint (31,32).

The non-significant relationship between TIRADs classification and both FINA results and elastography findings in the present study was revealed from other studies. Bojunga et al., (33) conducted a meta-analysis of research on real-time elastography for identifying benign from malignant thyroid nodules and concluded that elastography was advantageous for patients having surgery. In that meta analysis, 8 studies with a total of 639 nodules were examined, and the overall mean sensitivity

and specificity for the detection of malignant thyroid nodules were found to be 92 percent confidence interval (CI) 88–96 and 90 percent CI, 85–95, respectively. In another meta-analysis, Ghajarzadeh et al. (34) methodically analysed 12 papers that evaluated 1,180 thyroid nodules, and the diagnostic accuracy of sonoelastography in detecting malignant nodules was explored. They found that a threshold elasticity score of between 1 and 2 had the maximum sensitivity of 98.3 percent (95 percent CI, 96.2 percent–99.5 percent). They also stated that patients with an elasticity score of 1 did not require any more invasive testing.

Limitations

One of the limitations of the present study is the small sample size. Another limitation is being a single Centre study, so its results cannot be generalized.

Conclusion

In this study most patients (96.3%) had a benign tumor based on FINA results and 81.5% had a soft elastography. The most common TIRADs classification was the T2 (55.6%). Patients with a younger mean age had a significantly higher percentage of those who had T2 (TIRADs) and a non-significant relationship between TIRADs classification and FINA results. Females had a significantly higher percentage of having a benign diagnosis based on FINA results with a non-significant relationship found between FINA results and patients' demographic or clinical data. A non-significant relationship was found between both TIRADs classification and FINA results and the elastography findings. For more clarification of the study results, future studies on larger samples should be done.

References

1. Filho RHC, Pereira FL, Iared W. Diagnostic Accuracy Evaluation of Two-Dimensional Shear Wave Elastography in the Differentiation Between Benign and Malignant Thyroid Nodules: Systematic Review and Meta-analysis. *J Ultrasound Med.* 2020;39(9):1729–41.
2. Zhu L, Chen Y, Ai H, Gong W, Zhou B, Xu Y, et al. Combining real-time elastography with fine-needle aspiration biopsy to identify malignant thyroid nodules. *J Int Med Res.* 2020;48(12).
3. Lacout A, Chevenet C, Thariat J, Figl A, Marcy PY. Qualitative ultrasound elastography assessment of benign thyroid nodules: Patterns and intra-observer acquisition variability. *Indian J Radiol Imaging.* 2013;23(4):337–41.
4. Nell S, Kist JW, Debray TPA, De Keizer B, Van Oostenbrugge TJ, Rinke IHMB, et al. Qualitative elastography can replace thyroid nodule fine-needle aspiration in patients with soft thyroid nodules. A systematic review and meta-analysis. *Eur J Radiol [Internet].* 2015;84(4):652–61. Available from: <http://dx.doi.org/10.1016/j.ejrad.2015.01.003>
5. Cantisani V, David E, Grazhdani H, Rubini A, Radzina M, Dietrich CF, et al. Prospective Evaluation of Semiquantitative Strain Ratio and Quantitative 2D Ultrasound Shear Wave Elastography (SWE) in

- Association with TIRADS Classification for Thyroid Nodule Characterization. *Ultraschall der Medizin*. 2019;40(4):495–503.
6. Friedrich-Rust M, Meyer G, Dauth N, Berner C, Bogdanou D, Herrmann E, et al. Interobserver Agreement of Thyroid Imaging Reporting and Data System (TIRADS) and Strain Elastography for the Assessment of Thyroid Nodules. *PLoS One*. 2013 Oct 24;8(10).
7. Regmi S, Tiwari A, Sharma R. Comparison of Fine Needle Aspiration Cytology in Thyroid Lesions using The Bethesda System for Reporting Thyroid Cytopathology with Ultrasonography using Thyroid Imaging Reporting and Data System. *J Lumbini Med Coll*. 2018;6(2).
8. Yang X, Zhai D, Zhang T, Zhang S. Use of strain ultrasound elastography versus fine needle aspiration cytology for the differential diagnosis of thyroid nodules: A retrospective analysis. *Clinics*. 2020;75(7):1–8.
9. Borlea A, Borcan F, Sporea I, Dehelean CA, Negrea R, Cotoi L, et al. TI-RADS diagnostic performance: Which algorithm is superior and how elastography and 4D vascularity improve the malignancy risk assessment. *Diagnostics*. 2020;10(4):1–16.
10. Ríos A, Rodríguez JM, Torregrosa NM, Torregrosa B, Cepero A, Abellán MD, et al. Evaluation of the thyroid nodule with high-resolution ultrasonography and elastography without fine needle aspiration biopsy. *Med Clínica (English Ed)*. 2018;151(3):89–96.
11. Bojunga J, Herrmann E, Meyer G, Weber S, Zeuzem S, Friedrich-Rust M. Real-time elastography for the differentiation of benign and malignant thyroid nodules: A meta-analysis. *Thyroid*. 2010;20(10):1145–50.
12. Celletti I, Fresilli D, De Vito C, Bononi M, Cardaccio S, Cozzolino A, et al. TIRADS, SRE and SWE in INDETERMINATE thyroid nodule characterization: Which has better diagnostic performance? *Radiol Medica [Internet]*. 2021;126(9):1189–200. Available from: <https://doi.org/10.1007/s11547-021-01349-5>
13. Moon HJ, Sung JM, Kim EK, Yoon JH, Youk JH, Kwak JY. Diagnostic performance of gray-scale US and elastography in solid thyroid nodules. *Radiology*. 2012;262(3):1002–13.
14. Ünlütürk U, Erdogan MF, Demir Ö, Güllü S, Başkal N. Ultrasound elastography is not superior to grayscale ultrasound in predicting malignancy in thyroid nodules. *Thyroid*. 2012;22(10):1031–8.
- 15-Zimmermann MB, Galetti V. Iodine intake as a risk factor for thyroid cancer: a comprehensive review of animal and human studies. *Thyroid Res*. 2015 Jun 18;8:8. doi: 10.1186/s13044-015-0020-8. PMID: 26146517; PMCID: PMC4490680.
- 16-Rahbari R, Zhang L, Kebebew E. Thyroid cancer gender disparity. *Future Oncol*. 2010 Nov;6(11):1771–9. doi: 10.2217/fon.10.127. PMID: 21142662; PMCID: PMC3077966.
- 17-De D, Dutta S, Tarafdar S, Kar SS, Das U, Basu K, Mukhopadhyay P, Ghosh S. Comparison between Sonographic Features and Fine Needle Aspiration Cytology with Histopathology in the Diagnosis of Solitary Thyroid Nodule. *Indian J Endocrinol Metab*. 2020 Jul-Aug;24(4):349-354. doi: 10.4103/ijem.IJEM_349_20
- 18-Barbosa T, Junior C, Graf H, Cavalvanti T, Trippia M, da Silveira Ugino R, et al. ACR TI RADS and ATA US scores are helpful for the management of thyroid nodules with indeterminate cytology. *BMC Endocrine Disorders* 2019;19. 19- Kwak J, Han K, Yoon J, Moon H, Son E, Park S, et al. Thyroid imaging reporting and data system for US features of nodules: A step in establishing better stratification of cancer risk. *Radiology* 2011;260:892 9.
- 20- Yoon J, Lee H, Kim E, Moon H, Kwak J. Thyroid nodules: Nondiagnostic cytologic results according to thyroid imaging reporting and data system before and after application of the Bethesda system. *Radiology* 2015;276:579 87.
- 21- Singh Ospina N, Brito J, Maraka S, Espinosa de Ycaza A, Rodriguez Gutierrez R, Gionfriddo M, et al. Diagnostic accuracy of ultrasound guided fine needle aspiration biopsy for thyroid malignancy: Systematic review and meta analysis. *Endocrine* 2016;53:651 61
- 22- Kim EK, Park CS, Chung WY, et al. New sonographic criteria for recommending fine-needle aspiration biopsy of nonpalpable solid nodules of the thyroid. *AJR Am Roentgenol* 2002;178: 687–91.
- 23- Wienke JR, Chong WK, Fielding JR, et al. Sonographic features of benign thyroid nodules: interobserver reliability and overlap with malignancy. *J Ultrasound Med* 2003;22:1027–31.
- 24-2 Bloch M. Fine needle aspiration biopsy of head & neck masses. *Otolaryngol Head Neck Surg*. 1997;89:62–68. [Google Scholar]
- 25- Mundasad B, Mcallidter I, Carson J (2006) Accuracy of fine needle aspiration cytology in diagnosis of thyroid swelling. *Internet J Endocrinol* 2(2):23–25
- 26- Handa U, Garg S, Mohan H (2008) Role of fine needle aspiration cytology in diagnosis and management of thyroid lesion. *Indian J Pediatr* 25(1):13–17
- 27-Park SH, Kim SJ, Kim EK, et al. Interobserver agreement in assessing the sonographic and elastographic features of malignant thyroid nodules. *AJR* 2009;193:W416–23.
- 28- Itoh A, Ueno E, Tohno E, et al. Breast disease: clinical application of US elastography for diagnosis. *Radiology* 2006; 239:341–50.
- 29- Dighe M, Bae Unmin L, Michael, et al. Differential diagnosis of thyroid nodules with US elastography using carotid artery pulsation. *Radiology* 2008;248(2):662–9.
- 30- Kagoya R, Monobe H, Tojima H. Utility of elastography for differential diagnosis of benign and malignant thyroid nodules. *Otolaryngol Head Neck Surg* 2010;143:230–4.
- 31- Elniel HH, Ibrahim AE, Naglaa MA, et al. Real time ultrasound elastography for the differentiation of benign and malignant thyroid nodules. *Open J Med Imaging* 2014;4:38–47.
- 32- Kurita T. Clinical usefulness and future prospects of MicroPure. Toshiba Medical Website. www.toshiba-medical.co.jp/tmd/english/library/pdf/TMR-0808-1-MicroPure.pdf [accessed November 7: 2011.
33. Bojunga J, Herrmann E, Meyer G, Weber S, Zeuzem S, Friedrich Rust M. Real time elastography for the differentiation of benign and malignant thyroid nodules: A meta analysis. *Thyroid* 2010;20:1145 50.
34. Ghajarzadeh M, Sodagari F, Shakiba M. Diagnostic accuracy of sonoelastography in detecting malignant thyroid nodules: A systematic review and meta analysis. *AJR Am J Roentgenol* 2014;202:W379 89.